







Ligature technique as a treatment for mucocele in an infant - Case report

Beatriz Cruz Lopes¹ , Lucas Fernando Oliveira Tomaz Ferrarezzo¹ , Mariella Padovese¹ ,
Mariana Emi Nagata¹ , Farli Aparecida Carrilho Boer¹ , Cássia Cilene Dezan¹ .

Abstract: Mucocele is a common benign pathology of the minor salivary glands, caused by trauma that leads to rupture or obstruction of the glandular ducts. It is commonly found in children due to oral habits, such as biting and sucking on lips and cheeks. The main treatment consists of complete surgical excision of the lesion and associated gland, which can be traumatic and invasive for children. Therefore, conversational and short-term techniques have been developed to reduce patient discomfort. The objective of this study was to present a simplified technique for treating mucocele in infants, called Ligature, in order to reflect on the choice of the operative technique that allows for better trans and postoperative conditions. A four month-old male infant was referred to the Department of Oral Medicine and Children's Dentistry at the State University of Londrina for diagnosis and treatment of a nodular lesion on the inner mucosa of the lower lip. According to the clinical characteristics, a diagnosis of mucocele was reached, with the Ligature Technique as the treatment of choice. Local disinfection was performed followed by topical anesthesia and the base of the lesion was tied with suture. Monitoring until complete remission was carried out via telemonitoring between appointments due to the COVID-19 pandemic. The Ligature Technique is an excellent treatment option for pedicled mucoceles considering the importance of appropriate selection of dental techniques, in order to achieve the treatment goal in a less traumatic manner, and meet the specific needs of each patient.

Key words: Salivary Glands, Minor; Lip; Mucocele; Pediatric Dentistry.

Técnica de ligadura como tratamiento del mucocele en niños - Reporte de caso

Resumen: El mucocele es una patología benigna común de las glándulas salivales menores, provocada por un traumatismo que produce rotura u obstrucción de los canales glandulares. Se encuentra comúnmente en niños debido a hábitos bucales, como morderse o succionar labios y mejillas. El tratamiento principal consiste en la extirpación quirúrgica completa de la lesión y glándula asociada, que puede resultar traumática e invasiva para los niños. Por ello, se desarrollaron técnicas conversacionales y de corto plazo para reducir el malestar del paciente. El objetivo de este trabajo fue presentar una técnica simplificada para tratamiento del mucocele en lactantes, denominada Ligadura, con el fin de reflexionar sobre la elección de la técnica operatoria que permita mejores condiciones trans y postoperatorias. Un bebé masculino de cuatro meses fue remitido al Departamento de Medicina Oral y Odontología Infantil de la Universidad Estatal de Londrina para diagnóstico y tratamiento de lesión nodular en la mucosa interna del labio inferior. De acuerdo a las características clínicas se llegó al diagnóstico de mucocele, siendo el tratamiento de elección la técnica de Ligadura. Se realizó desinfección local seguida de anestesia tópica y se suturó la base de la lesión. El seguimiento hasta la remisión completa se realizó mediante telemonitorización entre citas debido a la pandemia de COVID-19. Por lo tanto, técnica de Ligadura es una excelente opción de tratamiento para mucoceles pediculados considerando la importancia de la selección adecuada de técnicas odontológicas, para lograr el objetivo del tratamiento de manera menos traumática y satisfaciendo las necesidades específicas de cada paciente.

Palabras clave: Glándulas salivales menores; Labio; Mucocele; Odontólogo pediátrico.

¹Departamento de Medicina Oral e Odontologia Infantil, Universidade Estadual de Londrina (UEL), Londrina, PR, Brasil.

Técnica de ligadura como tratamento para mucocele em bebês- Relato de caso

Resumo: A mucocele é uma patologia benigna comum das glândulas salivares menores, ocasionada por um trauma que provoca ruptura ou obstrução dos canais das glândulas. É comumente encontrada em crianças devido aos hábitos bucais, como morder e sucção de lábios e bochechas. O principal tratamento consiste na excisão cirúrgica completa da lesão e glândula associada, o que pode ser traumático e invasivo para crianças. Assim, foram desenvolvidas técnicas conversadoras e de curta duração para reduzir o desconforto dos pacientes. O objetivo deste trabalho foi apresentar uma técnica simplificada para tratamento da mucocele em lactentes, denominada de Ligadura, a fim de proporcionar uma reflexão mediante a escolha da técnica operatória que possibilite melhores condições trans e pós-operatórias. Lactente do sexo masculino, quatro meses, foi encaminhado ao departamento de Medicina Oral e Odontologia Infantil da Universidade Estadual de Londrina para diagnóstico e tratamento de lesão nodular em mucosa interna do lábio inferior. De acordo com as características clínicas, chegou-se ao diagnóstico de mucocele, tendo como tratamento de escolha a Técnica de Ligadura. Foi realizada desinfecção local seguida de anestesia tópica e amarração na base da lesão com fio de sutura. O acompanhamento até sua remissão total foi realizado por telemonitoramento entre as consultas devido à pandemia da COVID-19. Portanto, a Técnica de Ligadura é uma excelente opção de tratamento para mucoceles pediculadas tendo em vista a importância da seleção adequada das técnicas odontológicas, a fim de alcançar o objetivo do tratamento de forma menos traumática e atendendo às necessidades específicas de cada paciente.

Palavras-chave: Glândulas Salivares Menores; Lábio; Mucocele; Odontopediatria.

Introduction

Mucocele is the most common benign pathology of the minor salivary glands and occurs due to rupture or obstruction of the salivary ducts¹. It is asymptomatic¹, well-defined, soft on palpation², with a sessile or pedicled base and variable color and size that depend on the depth, elasticity of the tissue and location³. More common on the lower lip⁴ and in children and young adults, without sex predilection¹.

Treatment techniques vary between surgical excision, marsupialization, micromarsupialization, cryosurgery and steroid injection², all of which are unfeasible for outpatient care in babies, as these patients are unable to cooperate and require procedures with reduction of pain and clinical time.

The objective of this study is to present a simplified technique for treating pedicled mucoceles in babies, providing better trans and postoperative conditions.

Case report

Male patient, four months old, referred to the Children's Specialties Clinic of the State University of Londrina (UEL), for diagnosis and treatment of a nodular lesion present since birth and located on the inner mucosa of the lower lip. According to the mother, there was an increase in the size of the lesion and greater manipulation of the region by the baby, indicating discomfort, but without reports of pain.

On intraoral physical examination, a pedunculated nodule was observed,

with a smooth surface, soft to palpation, measuring approximately 2mm x 1mm (height x width) and a mucous-like color, consistent with the characteristics of a primary mucocele lesion (Figure 1). Considering the patient's age and the fact that they lived in a small town far from the university, the Ligature technique was chosen in a single session and in an outpatient setting. After obtaining the consent form, the procedure was carried out.

The patient was stabilized on a dental table and the technique was started: 1st) disinfection of the area with 0.12% chlorhexidine digluconate; 2nd) isolation of the region with the aid of gauze; 3rd) application of the ophthalmic anesthetic Tetracaine Hydrochloride 1% and Phenylephrine Hydrochloride 0.1% (Allergan®) with a cotton swab (Figure 2); 4°) creation of the tie at the base of the lesion with 5-0 silk suture thread, (Figure 3). 5°) Post-operative hygiene and follow-up instructions.

Due to the Covid-19 pandemic period, post-operative monitoring was carried out through tele monitoring with daily images and videos of the patient's oral cavity. On the first day, a reduction in the size of the mucocele was observed, but with the same clinical characteristics of color and shape. On the second day, the lesion appeared whitish-yellow, indicating reduced blood circulation in the region (Figure 4). On the third day, the injury had its complete remission. After a week, a satisfactory scarring appearance was observed in the region (Figure 5).

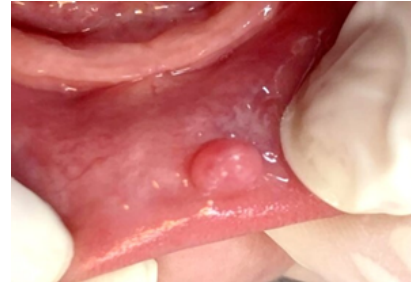

Figure 1. Initial state of the lesion located in the inner region of the lower lip.

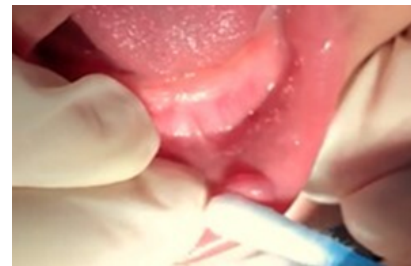

Figure 2. The region being anesthetized with topical ophthalmic anesthetic with the aid of a cotton swab.

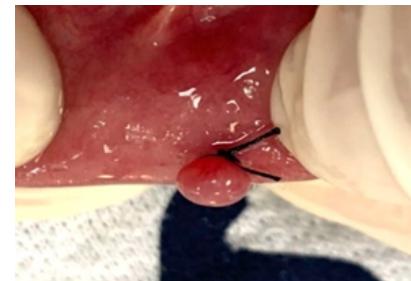

Figure 3. Ligature with silk suture placed at the base of the lesion.

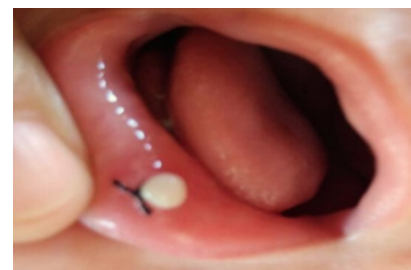


Figure 4. Appearance of the lesion on the second day of photo monitoring, with altered color ranging from mucous-like to whitish-yellow

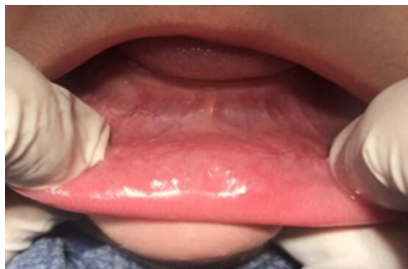

Figure 5. Final appearance of the inner mucosal tissue of the healed lower lip after 1 week of the procedure.

Discussion

When we refer to the treatment of these injuries in babies, it is necessary to think about techniques suitable for this age group, as they do not have the ability to cooperate with dental treatment, even with simplified techniques, such as micromarsupialization. Some techniques are difficult to perform because they require anesthetic infiltration and mucosal suturing. Furthermore, when using more invasive techniques, good hygiene of the operated site is essential to avoid postoperative infections, which is not always maintained by those responsible.

The Ligature technique, proposed by Children's Specialties Clinic of the State University of Londrina (UEL), consists of tying around the pedicled base of the lesion in order to block the blood supply and enable the lesion's remission process. It has the advantage of being able to be performed in an outpatient setting, quickly and practically, bringing patients greater collaboration and less discomfort during the procedure. It is an alternative treatment for mucoceles, indicated mainly for primary lesions, free of ulcerations, pedicle base, smooth surface, well defined, and may be bluish or translucent in color and soft on palpation.

Babies have a considerable prevalence of developing this type of lesion due to some oral habits during this period of life, such as biting and/or sucking their lips and cheeks and the frequent habit of pushing their tongue². In these cases, the Ligature technique becomes a relevant procedure in the area of pediatric dentistry, as patients generally have fears regarding the treatment and do not have the collaborative capacity like adults, due to the lack of psychological maturity and prior conditioning in most cases times^{5,6}.

With surgical excision as the gold standard procedure for the treatment of mucoceles, some disadvantages can be observed, firstly because it is a more traumatic technique for children, due to the use of infiltrative anesthesia and scalpel⁷, in addition to the longer healing time and discomfort. However, in cases where there is frequent trauma or secondary mucoceles, the recommendation is to surgically remove the glands associated concomitantly with the injury^{8,9}.

It is worth noting that both micromarsupialization¹⁰ and the Ligature technique are procedures that provide greater comfort to patients, making dental care more productive and less traumatic when compared to the conventional technique, as they are quick and easy to perform, do not require infiltrative anesthesia, have a good prognosis and low recurrence rate. However, the necessary period of sutures permanence used in micromarsupialization can cause discomfort and a greater probability of secondary infections^{7,9}, problems that the Ligature technique does not cause due to its greater

ease postoperative control and shorter treatment time.

Monitoring the case is a key factor in a good prognosis, regardless of the type of procedure chosen. The studies by Delbem¹⁰; Piazzetta¹¹ and Sagari⁷, demonstrated that during the follow-up period of 55 cases after micromarsupialization, 8 presented recurrence while of the 60 cases that opted for surgical excision, only 3 relapsed. In the present study, the Ligature technique did not show recurrence after 6 months of follow-up.

Conclusion

Considering the innovation of the Ligature technique and because it is not mentioned in the literature, this study sought to demonstrate that it is possible to develop problem-solving techniques through simpler means that meet the needs of the patient, who has particularities due to lack of knowledge, psychological development when compared to adults.

Conflict of Interest

The authors declare that they have no conflict of interest regarding the publication of this article.

References

1. Delli K, Spijkervet FK, Vissink A. Salivary gland diseases: infections, sialolithiasis and mucoceles. *Monogr Oral Sci.* 2014;24:135-48.
2. Choi YJ, Byun JS, Choi JK, Jung JK. Identification of predictive variables for the recurrence of oral mucocele. *Med Oral Patol Oral Cir Bucal.* 1º de março de 2019;24 (2):e231-5.
3. Lewandowski B, Brodowski R, Pakla P, Makara A, Stopyra W, Startek B. Mucoceles of minor salivary glands in children. Own clinical observations. *Dev Period Med.* 2016;20(3):235-42.
4. Neville WB, Damm DD, Allen CM, Bouquot JE. *Patologia das glândulas salivares.* in:--- *Patologia oral & maxilofacial*, 3ª ed, Rio de Janeiro: Elsevier. 2009:455-508.
5. American Academy of Pediatric Dentistry. Guideline on Pediatric Oral Surgery. *Pediatr Dent;* 2010;32(6):238-45.
6. American Academy of Pediatric Dentistry Behavior guidance for the pediatric dental patient. *Pediatr Dent.* 2015;40(6):254-67.
7. Sagari SK, Vamsi KC, Shah D, Singh V, Patil GB, Saawarn S, Micro-marsupialization: A minimally invasive technique for mucocele in children and adolescents. *J Indian Soc Pedod Prev Dent.* 2012;30:188-91.
8. Matondkar SP, Yavagal C, Mandroli PS. Modified micro-marsupialization as an alternative treatment for the management of ranulas in children. *Natl J Maxillofac Surg.* 2019;10(1):95-7.
9. Hegde S, Bubna K, Rao D. Management of Ranula in a Child by Modified Micro-Marsupialization Technique: A Case Report. *J Clin Ped Dent.* 41(4):305-07.
10. Delbem ACB, et al. Treatment of mucus retention phenomena in children by the micro-marsupialization technique: case reports. *Pediatr Dent.* 2000;22(2):155-58.
11. Piazzetta CM, Torres-Pereira C, Amenábar JM. Micro-marsupialization as an alternative treatment for mucocele in pediatric dentistry. *Int J Paediatr Dent.* 2012;22(5):318-23.

Recibido 14/02/24

Aceptado 10/06/24

Correspondencia: Beatriz Cruz Lopes, correo: beatriz.cruz.lopes@uel.br